

# The Estimate of the Impact of Coccyx Resection in Surgical Field Exposure During Abdominal Perineal Resection Using Preoperative High-Resolution Magnetic Resonance

Guilherme Pagin São Julião<sup>1</sup> · Cinthia D. Ortega<sup>2</sup> · Bruna Borba Vailati<sup>1</sup> · Francisco A. B. Coutinho<sup>3</sup> · Gustavo Rossi<sup>4</sup> · Angelita Habr-Gama<sup>1,5</sup> · Laura Melina Fernandez<sup>1</sup> · Sérgio Eduardo Alonso Araújo<sup>6</sup> · Gina Brown<sup>7</sup> · Rodrigo Oliva Perez<sup>1,6,8</sup>

© Société Internationale de Chirurgie 2018

## Abstract

**Objective** To estimate the improvement in surgical exposure by removal of the coccyx, during abdomino-perineal resection (APR), in rectal cancer patients.

**Methods** Retrospective study of 29 consecutive patients with rectal cancer was carried out. Using MR T2 sagittal series, the solid angle was estimated using the angle determined by the anterior resection margin and the tip of coccyx (no coccyx resection) or the tip of last sacral vertebra (coccyx resection). The solid angle provides an estimate of the tridimensional surface area provided by an original angle resulting in the best estimate of the surgeon's view/exposure to the critical dissecting point of choice (anterior rectal wall). The difference ("Gain") in surgical field exposure by removal of the coccyx was compared by the solid angle variation between the two estimates (with and without the coccyx).

**Results** Routine removal of the coccyx determines an average 42% (95% CI 27–57%) gain in surgical field exposure area facing the anterior rectal wall at the level of the prostate/vagina by the surgeon. Fifteen (51%) patients had  $\geq 30\%$  (median) estimated gain in surgical field exposure by coccygectomy. There was no association between BMI, age or gender and estimated gain in surgical field exposure area.

**Conclusions** Routine removal of the coccyx during APR may result in an average increase in 42% in surgical field exposure during APR's perineal dissection. Precise estimation of surgical field exposure gain by removal of the coccyx may be predicted by MR sagittal series for each individual patient.

✉ Rodrigo Oliva Perez  
rodrigo.operez@gmail.com

<sup>1</sup> Angelita and Joaquim Gama Institute, Rua Manoel da Nóbrega 1564, São Paulo, SP 04001-005, Brazil

<sup>2</sup> Radiology Department, University of São Paulo School of Medicine, Travessa da Rua Dr. Ovídio Pires de Campos, 75, São Paulo, SP 05403-010, Brazil

<sup>3</sup> Department of Pathology, University of São Paulo School of Medicine, Av. Dr. Arnaldo 455, São Paulo, SP, Brazil

<sup>4</sup> Hospital Italiano de Buenos Aires Colorectal Surgery Division, 4190 Perón St., 1199ABB Buenos Aires, Argentina

<sup>5</sup> University of São Paulo School of Medicine, Rua Manoel da Nóbrega 1564, São Paulo, SP 04001-005, Brazil

<sup>6</sup> Colorectal Surgery Division, University of São Paulo School of Medicine, Rua Manoel da Nóbrega 1564, São Paulo, SP 04001-005, Brazil

<sup>7</sup> Department of Radiology, The Royal Marsden NHS Foundation Trust, Downs Rd, Sutton SM2 5PT, UK

<sup>8</sup> Ludwig Institute for Cancer Research São Paulo Branch, Rua Manoel da Nóbrega 1564, São Paulo, SP 04001-005, Brazil

## Introduction

One of the main goals of distal rectal cancer surgery is to provide a proper specimen for the pathologist, commonly used as a surrogate marker for good local disease control [1]. An intact mesorectum, proper distal and circumferential margins (CRM) and the absence of tumor perforation are all considered to be of paramount importance for minimizing local recurrence rates [2]. Achievement of these features may be particularly challenging among patients with distal rectal cancer that require abdominal perineal resection (APR) due to tapering of the mesorectal fat, direct invasion of the intersphincteric plane, sphincter complex or levator muscles [1, 3, 4].

Several controversial issues remain unresolved during APR including the need for resection of the levator muscles (extralevator approach), the actual position of the patient during the perineal part of the procedure (prone jack-knife), the use of a mesh to close the perineal defect and the requirement for coccygeal resection [5, 6]. Even though resection of the coccyx may not be required for oncological reasons, it could potentially increase the surgical field exposure and aid in the dissection of the anterior rectal wall.

However, the impact of coccyx resection in surgical field exposure has never been objectively estimated preoperatively among actual patients with rectal cancer. Resection may result in specific clinical consequences including increased postoperative pain and larger perineal wound defects. Therefore, identification of patients in whom resection of the coccyx may result in increased gain in surgical field exposure may allow preoperative planning and individualized approach in coccyx resection during abdominal perineal resection. For these reasons, we decided to compare the estimate of surgical field exposure during the perineal part of the dissection of APRs by magnetic resonance with and without coccyx resection. The aim of the study was to quantify *in vivo* imaging the potential percentage gain in the surgical view exposure achieved by removal of the coccyx. Secondary objective was to determine potential factors to predict the degree of gain from such a removal.

## Materials and methods

Consecutive patients with rectal cancer located below the peritoneal reflection and undergoing baseline high-resolution MR were retrospectively studied after local IRB approval.

## MR

MRI with high-resolution sequences and a surface pelvic phased-array coil was performed as routinely used for primary staging of rectal cancer. The subjects were positioned in a feet-first position with the center of the coil placed above the pubic symphysis in order to obtain adequate signal from the lower rectum up to the mesorectum at the level of the promontorium as described previously [7].

No bowel preparation or rectal distention was performed. Intravenous antispasmodic agent immediately before the study was routinely used to reduce potential bowel motion artifacts. The protocol for a 1.5-T scanner included sagittal T2-weighted images using 20–24-cm field of view (FOV) including both pelvic sidewalls and 4-mm slices with no gap from one pelvic sidewall to the other including the promontorium, sacrum, coccyx and pubic symphysis. After sagittal sequences, T2W thin-section axial images perpendicular to the long axis of the rectum were obtained using 16–18-cm FOV and 3-mm slices with no intersection gap [8]. Diffusion-weighted images were obtained with b factors of 0 and 800 or 0 and 1000 s/mm<sup>2</sup>.

Pelvic MR imaging data were reviewed by a single expert radiologist to estimate differences in surgical field exposure with and without coccygeal resection based on sagittal images.

## Estimation of surgical field exposure

### *Surgical considerations*

We attempted to estimate the perineal surgical field exposure during the perineal part of the procedure considering our usual practice for the performance of APR. Since 2009, we routinely perform APR as a two-staged procedure being the abdominal part being performed in the lithotomy position (preferably by minimally invasive approach using standard laparoscopic instrumentation) [9]. Briefly, after high ligation of the inferior mesenteric artery, total mesorectal excision is performed down to the level of the coccyx posteriorly and the seminal vesicles or vaginal dome anteriorly. A sponge/gauze is placed posteriorly between the dissected mesorectum and the coccyx to be removed during the early steps of the perineal part of the procedure. Following the construction of the end colostomy and placement of a pelvic drain through one of the trocars, the patient is flipped over to the prone jack-knife position to allow perineal dissection. Here, extrasphincteric dissection is performed with routine resection of the coccyx to allow connection to the abdominal part of the dissection and incision of the levator muscles with identification of the gauze left posteriorly at the time of abdominal dissection. At this point, the specimen is everted

through the perineum to allow final dissection of the anterior rectal wall from the prostate/vagina until the entire specimen is removed from below.

### Imaging considerations

In order to estimate the surgeon's surgical field exposure at the point of coccyx resection and eversion of the specimen, we calculated the angles determined by the anterior line of dissection (at the level of the seminal vesicles/vagina) to the tip of the coccyx (mimicking no coccygeal resection) or the tip of the last sacral vertebra (mimicking coccygeal resection) in the median sagittal plane (Figs. 1, 2). Crossing of the lines (anterior rectal wall and connection to the tip of the coccyx/last sacral vertebra) was always at the same anatomical site for each patient and selected to determine angles (in both cases)  $\leq 90^\circ$  in order to avoid negative values for sin values.

### Solid angle

In geometry, a solid angle ( $\Omega$ ) is the two-dimensional angle in three-dimensional space that an object subtends at a point (Fig. 1). It is a measure of how large the object appears to an observer looking from that point. In the International System of Units (SI), a solid angle is expressed in a dimensionless unit called a steradian (sr) and is calculated as follows:

$$(\text{Solid Angle}) \Omega = \pi \cdot \sin^2 \theta$$

Therefore, the solid angle determined by the two-dimensional angle (determined by the angle  $[\theta]$  anterior line of dissection and a line to the tip of the coccyx/last

sacral vertebra) is the three-dimensional estimate of the surgeon's view/exposure of the surgical field at the time of connection between the perineal and abdominal dissection and initiation of dissection of the anterior rectal wall following specimen eversion.

### Gain in solid angle

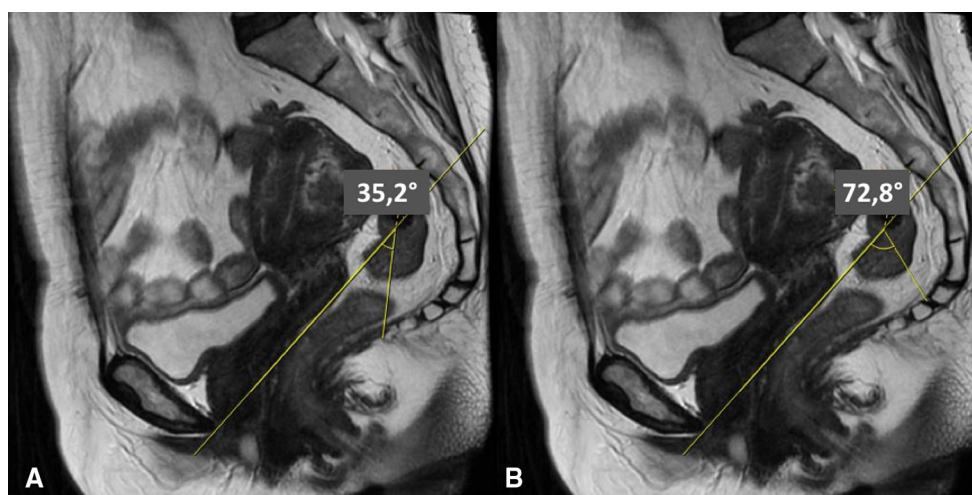
In order to estimate the difference in surgical field exposure by removal of the coccyx, we compared the solid angle variation between the two estimates (with and without the coccyx) (Fig. 3). Even though the estimate of the solid angle requires a specific distance from the original angle to be determined, considering the distance would be the same for the procedure with or without coccygeal resection, the exact distance for solid angle gain calculation becomes irrelevant [10]. The variation in solid angle is then provided in percentages and is solely dependent on the angles created by the lines of the anterior rectal wall and the tip of the coccyx (mimicking coccyx preservation— $\beta$ ) or the last sacral vertebra (mimicking coccyx resection— $\alpha$ ) as follows:

Gain in Solid Angle:

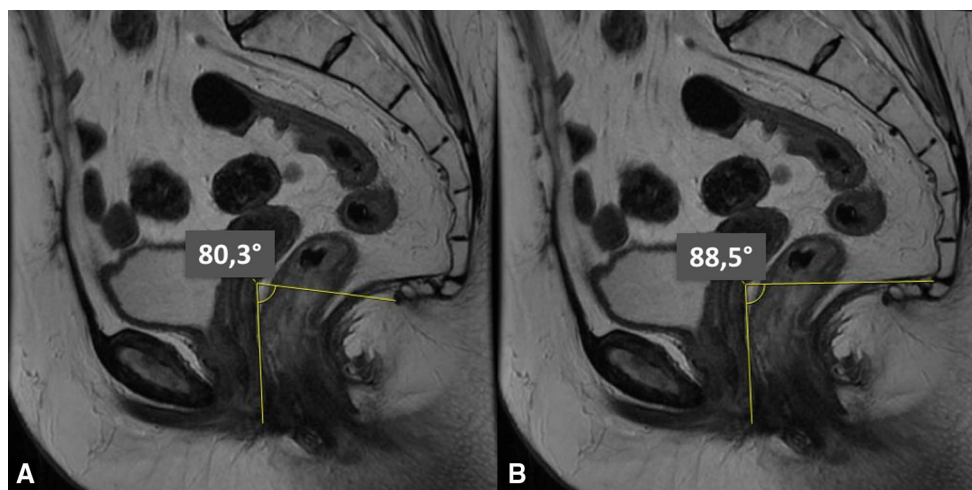
$$\frac{\sin^2 \beta - \sin^2 \alpha}{\sin^2 \alpha}$$

## Results

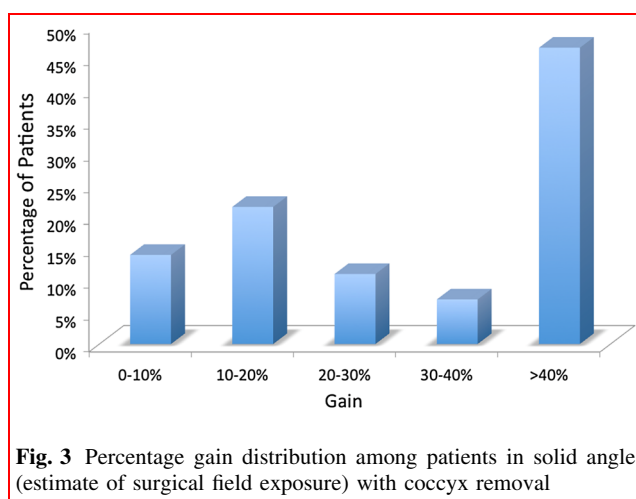
Overall, 29 consecutive patients with extraperitoneal rectal cancers were included. Patient demographics are available in Table 1. Overall, the estimated average gain determined by removal of the coccyx would be of 42% (95% CI



**Fig. 1** Variation in angles determined by anterior rectal wall resection line and the tip of the coccyx (a) or the last sacral vertebra mimicking coccygeal resection during APR (b). In the present example, the estimated gain in solid angle by removal of the coccyx would be of 174%



**Fig. 2** Variation in angles determined by anterior rectal wall resection line and the tip of the coccyx (a) or the last sacral vertebra mimicking coccygeal resection during APR (b). In the present example, the estimated gain in solid angle by removal of the coccyx would be of 2.8%



**Fig. 3** Percentage gain distribution among patients in solid angle (estimate of surgical field exposure) with coccyx removal

**Table 1** Patients demographics

<i>N</i>	29 (100%)
Male–female	20–9 (68.9–31.1%)
BMI (kg/m <sup>2</sup> )	26.7 ± 4.5
Height (cm)	169.1 ± 7.2

27–57%) of the original estimate in solid angle (median 30%). Nineteen patients (65%) had  $\geq 20\%$  in estimated gain in surgical field exposure by removal of the coccyx, while 15 (51%) had  $\geq 30\%$  estimated gain (Fig. 1). Only 4 patients (nearly 15% of our series) had  $\leq 10\%$  gain in surgical field estimate by resection of the coccyx (Fig. 2). There was no association between BMI, age or gender and

**Table 2** Risk factors for gain over 30% with coccygectomy

	Gain $\geq 30\%$	Gain $< 30\%$	<i>p</i>
<i>N</i>	15	14	
Male–female	11–4 (73.3–26.7)	9–5 (64.3–35.7)	0.450
BMI (kg/m <sup>2</sup> )	25.9 ± 1.2	27.5 ± 1.1	0.321
Height (cm)	170.3 ± 2.0	167.8 ± 1.7	0.346

estimated gain ( $\geq 30\%$ ) in surgical field exposure area by removal of the coccyx (Table 2).

## Discussion and conclusion

The achievement of a proper surgical specimen with negative CRM and the absence of fragmentation/tumor perforation may be challenging in patients undergoing APR for distal rectal cancer [4]. Most commonly, these patients present with low-lying cancers and exhibit poor response to neoadjuvant chemoradiation (nCRT) or even after local recurrences following previous surgical resection [9]. Therefore, the plane of dissection among these patients will require a more wide extension (extralevator) leaving the mesorectal plane for the less common indications for APR (higher location associated with fecal incontinence or early rectal tumors) [11]. In an attempt to decrease the risk for CRM+ and intraoperative perforation/fragmentation of the specimen, specific technical steps during APR have been suggested to minimize the risks for these surgical outcomes [12]. The performance of the extralevator approach commonly includes perineal dissection in the prone position



after full completion of the abdominal dissection and routine resection of the coccyx [13]. Coccygeal resection is less frequently required for oncological reasons (direct extension of the primary cancer). Instead, this resection has been suggested to facilitate the communication between perineal and abdominal dissection and subjectively increase surgical field exposure [13]. Our data provide objective estimate of an average 42% surgical field exposure gain by removal of the coccyx during the procedure. Nearly two out of three patients undergoing the procedure will have  $\geq 30\%$  gain in surgical field exposure by performing this simple step of the operation, whereas less than 15% will have  $\leq 10\%$  increase in surgical field exposure estimate.

These observations add another relevant aspect of preoperative MR assessment in surgical and treatment planning of these patients. Baseline staging provided by MR allows proper identification of high-risk features for the development of local recurrence following radical surgery aiding in the selection of patients for neoadjuvant treatment prior to radical surgery [14]. In addition, MR may indicate the plane of dissection required during APR by identifying patients that require an extralevator approach in order to achieve a proper surgical specimen [11]. Also, preoperative imaging may already suggest intraoperative difficulties related to the sizes of the residual tumor, the mesorectal envelope and prostate (in male patients). Here, our data suggest that MR may also provide important information for surgeons to anticipate the benefit in terms of the estimate in surgical field exposure gain by coccygeal resection during APR, particularly in challenging cases with large residual tumors and mesorectal envelopes. The estimate of the solid angle gain in these patients may allow for the tailored approach in surgical strategy to individualize patients that benefit the most from coccygeal resection when there is significant gain in surgical field exposure estimate even when resection is not required for oncological reasons such as direct invasion of the primary to the coccyx. In contrast, patients with minimal gain in surgical field exposure (and perhaps in the presence of other favorable features such as small residual tumor volume and mesorectal envelopes) may be spared from unnecessary resection and its associated morbidity (significantly worse postoperative pain) and increase in perineal wound defect [15, 16].

Our study has several limitations that should be considered prior to definitive implementation of our findings into routine clinical practice. First of all, it is still unclear whether resection of the coccyx provides any benefit in terms of quality of the surgical specimen, oncological outcomes or postoperative morbidity. This information could only be obtained in the setting of a study comparing APR with or without coccygeal resection, preferably in a

randomized fashion and is beyond the scope of the present study. Also, solid angle estimate has also not been validated as a surrogate for improved surgical performance or quality of the specimen. Ultimately, these outcomes may still be highly dependent on the surgeon and less dependent on surgical field exposure itself. In other words, skilled surgeons may perform better with or without increased surgical field view, whereas less skilled surgeons may perform poorly regardless of surgical access. It also remains to be determined the actual cutoff of gain in surgical field exposure that may translate into improved surgical outcomes. Even though a 5% gain may be clinically relevant in a difficult male obese patient, a 15% gain may be irrelevant in an easy thin female patient.

Despite the presence of these significant limitations of the present study, it still suggests the clinical/surgical utility of a novel and objective parameter that is easy to measure and readily provided by standard preoperative radiological imaging. In this setting, it may allow future studies to attempt to correlate this parameter with surgical and oncological outcomes.

In conclusion, preoperative MR may provide relevant information in patients with distal rectal cancer allowing an objective estimate of the improvement in surgical field exposure from the perineal dissection performed during an APR. Calculation of the solid angle gain with and without coccygeal resection shows a significant increase in the estimate of the surgical exposure with the former approach. In average, coccyx resection will determine a 42% gain in such estimate and may potentially facilitate dissection, especially during resection of the anterior rectal wall following eversion of the specimen, and minimize the risk for CRM+ and intraoperative perforation/fragmentation of the specimen. This may allow future selection of patients that benefit the most from coccygeal resection during APR. Future studies should include the estimate of the gain in surgical field exposure to address the impact of coccygeal resection in specific validated surgical and pathological surrogates for oncological outcomes.

## References

1. Nagtegaal ID, van de Velde CJ, Marijnen CA et al (2005) Low rectal cancer: a call for a change of approach in abdominoperineal resection. *J Clin Oncol* 23:9257–9264
2. Bosch SL, Nagtegaal ID (2012) The importance of the pathologist's role in assessment of the quality of the mesorectum. *Curr Colorectal Cancer Rep* 8:90–98
3. Shihab OC, Brown G, Daniels IR et al (2010) Patients with low rectal cancer treated by abdominoperineal excision have worse tumors and higher involved margin rates compared with patients treated by anterior resection. *Dis Colon Rectum* 53:53–56

4. How P, Shihab O, Tekkis P et al (2011) A systematic review of cancer related patient outcomes after anterior resection and abdominoperineal excision for rectal cancer in the total mesorectal excision era. *Surg Oncol* 20:e149–155
5. Prytz M, Angenete E, Bock D et al (2016) Extralevator abdominoperineal excision for low rectal cancer-extensive surgery to be used with discretion based on 3-year local recurrence results: a registry-based, observational national cohort study. *Ann Surg* 263:516–521
6. de Campos-Lobato LF, Stocchi L, Dietz DW et al (2011) Prone or lithotomy positioning during an abdominoperineal resection for rectal cancer results in comparable oncologic outcomes. *Dis Colon Rectum* 54:939–946
7. Sao Juliao GP, Ortega CD, Vailati BB et al (2017) Magnetic resonance imaging following neoadjuvant chemoradiation and transanal endoscopic microsurgery for rectal cancer—key diagnostic features of local recurrences. *Colorectal Dis* 19:O196–O203
8. Brown G, Daniels IR, Richardson C et al (2005) Techniques and trouble-shooting in high spatial resolution thin slice MRI for rectal cancer. *Br J Radiol* 78:245–251
9. Habr-Gama A, Sao Juliao GP, Mattacheo A et al (2017) Extralevator abdominal perineal excision versus standard abdominal perineal excision: impact on quality of the resected specimen and postoperative morbidity. *World J Surg*. <https://doi.org/10.1007/s00268-017-3963-1>
10. Naito M (1957) A method of calculating the solid angle subtended by a circular aperture. *J Phys Soc Jpn* 12:1122–1129
11. Shihab OC, How P, West N et al (2011) Can a novel MRI staging system for low rectal cancer aid surgical planning? *Dis Colon Rectum* 54:1260–1264
12. West NP, Anderin C, Smith KJ et al (2010) Multicentre experience with extralevator abdominoperineal excision for low rectal cancer. *Br J Surg* 97:588–599
13. Shihab OC, Heald RJ, Holm T et al (2012) A pictorial description of extralevator abdominoperineal excision for low rectal cancer. *Colorectal Dis* 14:e655–660
14. Taylor FG, Quirke P, Heald RJ et al (2011) Preoperative high-resolution magnetic resonance imaging can identify good prognosis stage I, II, and III rectal cancer best managed by surgery alone: a prospective, multicenter, European study. *Ann Surg* 253:711–719
15. Wang YL, Dai Y, Jiang JB et al (2015) Application of laparoscopic extralevator abdominoperineal excision in locally advanced low rectal cancer. *Chin Med J (Engl)* 128:1340–1345
16. Han JG, Wang ZJ, Qian Q et al (2014) A prospective multicenter clinical study of extralevator abdominoperineal resection for locally advanced low rectal cancer. *Dis Colon Rectum* 57:1333–1340